

Acquired and Reversible Pelger-Huët Anomaly of Polymorphonuclear Neutrophils in Three Transplant Patients Receiving Mycophenolate Mofetil Therapy

Lars M. Asmis,^{1*} Karine Hadaya,² Pietro Majno,³ Christian Toso,³ Frédéric Triponez,³ and Michel Starobinski¹

¹Division of Hematology, Geneva University Hospital, Switzerland

²Division of Nephrology, Geneva University Hospital, Switzerland

³Department of Surgery, Geneva University Hospital, Switzerland

Deficient nuclear segmentation and abnormal chromatin condensation define Pelger-Huët anomaly of polymorphonuclear neutrophils. Next to the hereditary irreversible form, acquired forms both reversible and irreversible have been described. We describe three transplant patients who were all investigated for a left shift in the absence of symptoms or signs of infection and in whom acquired reversible Pelger-Huët anomaly was discovered. The abnormal PMN phenotype was induced by mycophenolate mofetil (MMF). MMF is a necessary but not sufficient condition for the development of the anomaly. In our three patients a dose-response effect was observed regarding plasma MMF concentration and severity of neutrophil dysplasia. Except for one slightly elevated value, the patients' plasma MMF levels were within the therapeutic range. None of the patients, one who was neutropenic at presentation and two who were non-neutropenic, developed infectious complications. From our three cases as well as those of other authors, we identify previous graft rejection episodes as a potential predisposing factor for the development of PHA. In the first patient, drug withdrawal led to normalization of PMN morphology. In the other two patients, the left shift disappeared after dose reduction. In these latter two patients, a form of desensitization to the effect of MMF on neutrophils was observed following re-augmentation of MMF dose. *Am. J. Hematol.* 73:244–248, 2003. © 2003 Wiley-Liss, Inc.

Key words: acquired Pelger-Huët anomaly; left shift; mycophenolate mofetil; neutrophil dysplasia; segmentation index

INTRODUCTION

Two Dutch physicians, Pelger and Huët, first described deficient nuclear segmentation of polymorphonuclear neutrophils (PMN) in association with abnormal chromatin condensation in 1928 and 1931 as a hereditary anomaly [1,2]. Incidence of the heterozygous form is approximately 1:2,000 to 1:5,000 in Europe, with regional variations. The distribution of the anomaly is worldwide. Inheritance is autosomal intermediary; i.e., the heterozygous phenotype differs from the wild type as well as from its homozygous counterpart. The segmentation defect characteristic of Pelger-Huët anomaly (PHA) leads to abnormal PMN with mostly round and some oval nuclei in the homozygous form and abnormal PMN with mainly hypolobulated (oval and bilobed) nuclei in the heterozygous form. In contrast to the altered

nuclear maturation, the cytoplasmic maturation of these cells proceeds normally. The result is a polymorphonuclear neutrophil with a round or oval nucleus and nor-

This work was published in abstract form at the Meeting of the Swiss Society of Hematology in Lausanne, Switzerland, 10–12 May, 2001.

Contract grant sponsor: Swiss Foundation for Medical-Biological Grants; Contract grant number: 1087.

*Current address of Lars M. Asmis to whom correspondence should be addressed: Johns Hopkins Medical Institutions, Division of Hematology, 720 Rutland Ave., Baltimore, MD 21205.
E-mail: lars.asmis@jhmi.edu

Received for publication 28 October 2002; Accepted 15 April 2003

Published online in Wiley InterScience (www.interscience.wiley.com).
DOI: 10.1002/ajh.10359

TABLE I. Patients' Medications, Hemograms, and Assessment of Nuclear Segmentation

	Medication				Hemogram			Assessment of nuclear segmentation							
	Time	MMF	Pred	FK506	WBC	NSeg	Seg	0	1	2	3	4	5	6	mSI
Case 1	6.75	2	12.5	4	2.7	34	16	26	61.5	12	0.5	0	0	0	0.87
	8.50	0	10	2	6.8	1*	68	1.5	3	21	37	29.5	7.5	0.50	3.15
Case 2	6.75	1	10	5	4.1	33	30	4	55.5	29	7.5	3	1	0	1.53
	7.50	0.5	10/7.5	5	4.0	5	64	0	17.5	39.5	30	11.5	1.5	0	2.40
	9.25	1	7.5	6	5.7	5.5	59	0	15.5	38	26.5	17	3	0	2.54
	13.00	1	4	7	3.6	2.5	65	0	6.5	24.5	38.5	27	3	0.5	2.97
Case 3	6.25	1.5	7.5	5	7.7	26	43	6	35	30.5	17.5	7.5	3.5	0	1.96
	6.75	1	7.5	5	8.0	14	65	6	23.5	38	12.5	12.5	6	1.5	2.26
	7.00	0.5	7.5	5	6.1	15	61	4	18.5	30	15	20.5	11	1	2.67
	11.00	1	7.5	5	6.7	0.5 ^a	75	0.5	1.5	5	18.5	37	27	13 ^b	4.18

*Abbreviations and units: time, months post-transplantation; mycophenolate mofetil (MMF), g/day; prednisone (Pred), mg/day; FK506, mg/day; white blood cells (WBC), $\times 10^9/l$; non-segmented PMN (N_{Seg}), %; segmented PMN (Seg), %; modified segmentation index (mSI), nihil.

^a0.5% myelocytes.

^bPlus 3 PMN with 7 and 1 PMN with 8 segments

mal cytoplasmatic features. Mutations of the lamin B receptor, a receptor located on the inner nuclear membrane and which binds heterochromatin and lamins, have been shown to be associated with the familial form of PHA [3].

Acquired forms of PHA have been described. They can be classified as reversible or irreversible and may present as hetero- or homozygous phenotypes or phenocopies. Acquired PHA is mainly known as a feature of myelodysplasia, but it has also been described with other hematologic disorders such as myeloproliferative and lymphoproliferative syndromes as well as acute leukemias [for reviews see 4 and 5]. Acquired PHA has also been reported to occur with different infectious disorders [1,6–8], following bone marrow transplantation [9–11], as well as in association with various medications [11–21].

Banerjee et al. have previously described two transplant patients who presented neutrophil dysplasia, which preceded the development of neutropenia in association with MMF [22]. In three patients with the same neutrophil dysplasia, we show that this dysplasia corresponds to acquired Pelger-Huët anomaly, define diagnostic criteria for this adverse drug effect, show a dose–response relationship, introduce a parameter permitting the quantification of severity (the modified segmentation index), and, for two of our patients, describe a form of desensitization to the dysplastic effect of the drug following dose diminution and subsequent re-augmentation.

PATIENTS AND METHODS

Three patients, two male and one female, 47, 64, and 71 years of age, received a liver transplant, a combined kidney/pancreas transplant, and a kidney transplant because of hepatitis C-induced cirrhosis, type I diabetes-

induced complications, and terminal renal insufficiency due to polycystic kidney disease, respectively. Within the first month after their transplantation, all had suffered from acute graft rejection that responded to standard treatment.

Four, 5, and 8 months after their respective operations, they presented a left shift on their peripheral blood smears. At this time none of the patients was suffering from rejection reactions and none presented any signs or symptoms of an ongoing infection. Transaminases, alkaline phosphatase, and bilirubin were within normal limits at presentation in all three patients. Protein levels in patients 1 and 2 (62 and 64 g/l, normal range 61–79 g/l) and albumin levels in patients 2 and 3 (38 g/l and 40 g/l, normal range 35–48 g/l) were normal. Creatinine values were normal in patient 1, slightly elevated in patient 2 (95 $\mu\text{mol/l}$, normal range 35–88 $\mu\text{mol/l}$), and moderately elevated in patient 3 (160 $\mu\text{mol/l}$, normal range 62–106 $\mu\text{mol/l}$). The immunosuppressive regimen of the three patients at the time of presentation was composed of FK506 (tacrolimus), mycophenolate mofetil, and prednisone (see Table I). Other prescribed medications included insulin (patients 1–3), enalapril (patient 1), felodipine (patient 1), nifedipine (patient 2), clonidine (patient 2), omeprazole (all patients), cisapride (patient 2), citalopram (patient 1), lamivudine (patient 1), fluconazole (patients 2 and 3), sulfadoxine/pyrimethamine (patients 2 and 3), erythropoietin (patient 2), torasemide (patient 3), allopurinol (patient 3), and simvastatin (patient 3).

We relied on the presence of three phenotypic criteria for the diagnosis of PHA: abnormal nuclear segmentation of PMN (presence of left shift and an abnormal modified segmentation index [mSI]); abnormal chromatin condensation (lumpy chromatin, no nucleoli); presence of cytoplasmatic features of maturation (secondary

granules, staining). Inherited PHA was excluded in our patients as they all have had a normal peripheral blood smear at one point in time.

Pelger-Huët cells were distinguished from other circulating cells with round nuclei by their morphological characteristics: variable medium-to-low nucleocytoplasmatic ratio, mottled chromatin, absence of nucleoli, pale cytoplasm, presence of secondary neutrophilic granules. They differ from myelocytes that have a similar or larger nucleocytoplasmatic ratio, often have a nucleolus, have a more stainable pink or lilac cytoplasm, and contain more primary azurophilic granules. There are two other cell types with a similar nucleocytoplasmatic ratio as homozygous Pelger-Huët cells: large granular lymphocytes and plasma cells. The former have a relatively finer chromatin structure, sometimes nucleoli, more basophilic cytoplasm, and contain some rare azurophilic granules. The latter are easily identified by their more basophilic cytoplasm with the prominent Golgi zone and the absence of granulation.

Nuclear segmentation in PMN was defined by the $\frac{1}{3}$ method, according to which any indentation which is $>\frac{2}{3}$ of the transverse nuclear diameter was regarded as significant. Hence a PMN with one significant indentation has two segments, a PMN with two significant indentations has three segments, etc. We evaluated 200 nuclei of PMN regarding segmentation. The segmentation index (SI), also known as the average lobe index, was calculated by adding the total number of segments per 100 PMN [23]. We introduce a modified SI (mSI) where round nuclei (minimal diameter $> \frac{1}{2}$ maximal diameter) are considered to have zero segments and oval nuclei one segment. This modification permits a differentiation of homozygous (mSI < 1) and heterozygous phenotypes (mSI ≥ 1). These cut-off values were defined following analysis of publications describing cases of homozygous Pelger-Huët patients [24–28]. In normal propositi the mSI is 2.97 [23,29]. Left shift was evaluated on peripheral blood smears by counting 200 leukocytes and was defined by more than 5% of leucocytes being PMN with less than two segments.

Plasmatic drug levels were measured using an enzyme-mediated immune transfer (EMIT) assay (Dade Behring, San Jose, CA) by the Central Laboratory for Clinical Chemistry at the Geneva University Hospital. The therapeutic plasma concentration of mycophenolic acid (MPA), the active metabolite of MMF, is considered to be 3–7 mg/l.

RESULTS

Using WHO criteria for the diagnosis and classification of *adverse drug reactions* [30], the type of reaction we describe can be characterized as being *dose related*

and time related, and its causality can be evaluated as *probable*.

The first patient presented a phenotype corresponding to the homozygous form of the inherited disorder (mSI < 1 : more than 96% of PMN were round or non-segmented), whereas the other two presented with a heterozygous phenotype [23].

PMN morphology normalized after drug withdrawal in the first patient (Fig. 1). In the other two, in whom MMF treatment was considered essential for graft survival, the left shift disappeared after dose reduction.

Figure 2 illustrates a dose–response relationship between plasma MPA concentration [MPA] and mSI. Table I illustrates the immunosuppressive regimen, the associated hematological changes and analysis of nuclear segmentation for the three patients.

DISCUSSION

Acquired “neutrophil dysplasia” due to MMF has previously been described by Banerjee et al. [22]. They describe the morphologic variant in two transplant patients in whom the dysplasia disappears following drug discontinuation. We identify the dysplasia in our three patients as being acquired and reversible Pelger-Huët anomaly. This a significant adverse drug effect in the sense that it led to additional investigations in all three patients and prolonged hospitalization in one of them.

The underlying mechanism how MMF leads to the altered neutrophil phenotype is unknown. Once absorbed the prodrug MMF is rapidly converted by esterases to mycophenolic acid (MPA), which is the active metabolite. MPA is subsequently glucuronidated to the inactive mycophenolic acid glucuronide (MPAG) by UDP-glucuronyl transferases and excreted primarily in the urine [31,32]. MPAG also undergoes enterohepatic recycling via the bile. The three patients had normal plasmatic drug levels and normal protein and/or albumin levels (MPA binds avidly to albumin, free MPA is biologically active) at the time of presentation. Systemic MPA accumulation seems an unlikely explanation. Local MPA accumulation for instance due to tissue specific metabolism is an interesting hypothesis. In fact different UDP-glucuronyl transferase isoenzymes have been described in different tissues (liver, intestine, stomach, kidney) [31]. Individually varying therapeutic and toxic ranges for MMF are alternative explanations.

All of our patients received FK506 (tacrolimus) that has recently been described to induce PHA [11]. In our three cases PHA phenotype disappeared and/or the mSI increased despite the same or even increased FK506 doses (see Table I). Hence it cannot be made responsible for the altered PMN phenotype in our three patients. No other reported cause of acquired PHA could be identi-

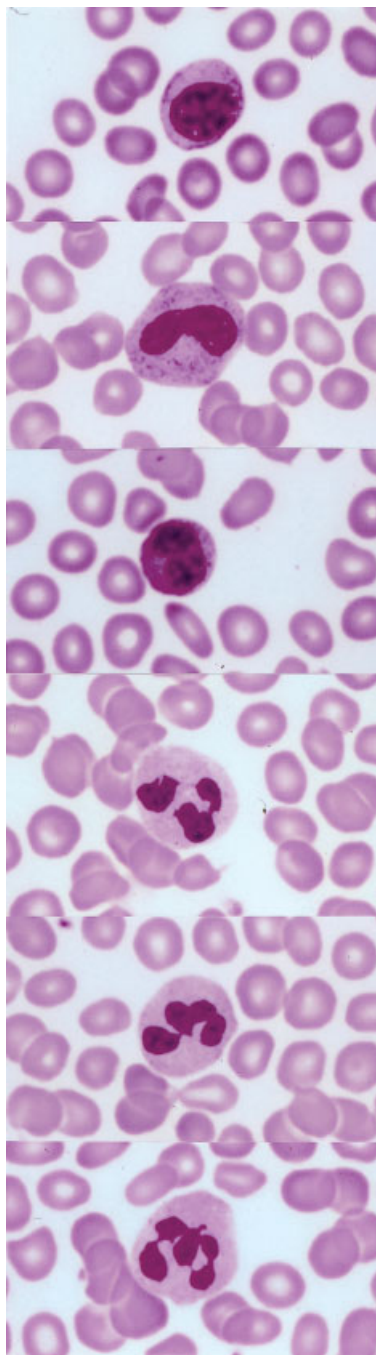


Fig. 1. Neutrophils of case 1 with (from top to bottom) 0, 1, 2, 3, 4, and 5 segments (Wright's stain, original magnification 50 \times). The upper three pictures were taken when the patient received MMF, the lower three after drug withdrawal.

fied. Management consisted of MMF withdrawal in the first and dose reduction in the other two cases.

An intriguing question remains why some patients develop PHA, whereas most patients treated with MMF do not. In affected patients MMF appears to be a necessary condition without being sufficient. The only common event we could find in the reports of Banerjee et al. and

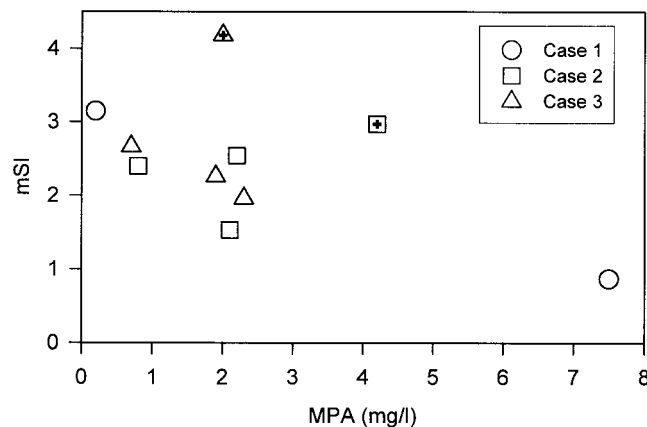


Fig. 2. PMN segmentation abnormalities due to MMF: the modified segmentation index (mSI; value in healthy controls: 3.0) is depicted as a function of MPA plasma concentration [MPA] in mg/l (therapeutic range: 3–7 mg/l). "Habituation" to MMF developed after 5–6 months in patients 2 and 3. These two values (13 and 11 months post-transplantation, see Table I) are marked by a "+".

Gondo et al. is that all patients at one time suffered graft rejection. All our patients suffered graft rejection as well but these episodes preceded the development of PHA by 6 months or more and no signs of rejection were noted upon presentation of PHA. There is preliminary evidence in animals, however, that graft rejection can acutely alter UDP-glucuronyl transferase activity at a tissular level [33]. Whether such changes could lead to acquired PHA remains to be seen. Other factors that may predispose patients to develop PHA might be genetic predisposition (polymorphism in enzymes responsible for drug metabolism or drug action), immunosuppression per se, and the transplantation context. Two of our patients presented some form of renal insufficiency but no correlation could be shown between the morphologic alterations and the evolution of the plasma creatinine levels.

In patients 2 and 3, development of some form of desensitization is suspected (Fig. 2): 5–6 months after the initial dose reduction and 3–4 months following subsequent increases in dosage, the patients showed only very subtle morphological alterations in the absence of a left shift or decreased mSI, despite MMF concentrations that were previously associated with PHA.

As none of the patients suffered infectious complications throughout the period that they presented the altered PMN phenotype, there are no arguments speaking in favor of diminished PMN function. In view of the leuko- and neutropenia which patient 1 presented initially, an increased infectious risk cannot be ruled out in the most severe forms of MMF induced PHA. Both PHA cases described by Banerjee et al. were associated with discrete neutropenia [22].

PMN segmentation and chromatin condensation are mediated by processes such as filament formation

(known in formation of “drum sticks”) and transcriptional silencing (known in yeast or *Drosophila* and inactivation of X chromosomes) [34]. Whether the PMN dysplasia we describe is mediated by a known effect of MMF [32], such as altered purine metabolism or inhibition of protein glycosylation, or an unknown one remains to be seen. The recent discovery that mutations of the lamin B receptor have been shown to be associated with the hereditary form of PHA direct future research toward ligands of this receptor or downstream signal transduction events. Acquired Pelger-Huët anomaly due to MMF may indeed prove to be a model that permits further elucidation of the mechanisms underlying the nuclear changes observed in neutrophil maturation.

In conclusion, we have presented three cases of acquired and reversible Pelger-Huët anomaly “probably” induced by MMF in transplant patients, which when treated by drug withdrawal (in one neutropenic patient) or dose reductions (in two non-neutropenic patients) were not associated with infectious complications. All patients had previously suffered graft rejection episodes. Interestingly, a form of tolerance could be observed following re-augmentation of MMF dosage in the latter two patients. Finally, we propose the absolute neutrophil count and the modified segmentation index, mSI, as parameters to monitor severity and follow-up evolution.

NOTE ADDED IN PROOF:

Recently, Kennedy GA et al. (Pathology 2002;34:263–266) have described a Pelger-Huët like appearance of neutrophils in 5 patients following renal transplantation. The authors suggest that the combination of ganciclovir with MMF is critical for its development. We note that none of our patients was treated with ganciclovir when the dysplastic changes were noted as well as at least 3 months prior to their onset.

REFERENCES

- Pelger K. Demonstratie van een paar zeldzaam voorkomende typen van bloedlichaampjes en bespreking der patienten. Ned Tijdschr Geneesk 1928;72:1178.
- Huët GJ. Familiaire anomalie der leucocyten. Ned Tijdschr Geneesk 1931;75:5956–5959.
- Hoffmann K, Dreger CK, Olins AL, et al. Mutations in the gene encoding the lamin B receptor produce an altered nuclear morphology in granulocytes (Pelger-Huët anomaly). Nat Genet 2002;31(4):410–414.
- Hennekeuser H-H, Fischer R, Talke H, Mainzer K. Pseudo-Pelger-Zellen vom homozygoten Typ bei unreifzelliger myeloischer Leukämie. Dtsch Med Wochenschr 1969;44:2284–2288.
- Morel P. Anomalie de Pelger-Huët. Lyon Med 1972;228(17):449–455.
- Cordas S, Briner DH. Acquired Pelger-Huët anomaly associated with infectious mononucleosis. J Am Osteopath Assoc 1967;66(12):1347–1355.
- Shenkenberg TD, Rice L, Waddell CC. Acquired Pelger-Huët nuclear anomaly with tuberculosis. Arch Intern Med 1982;142(1):153–154.
- van Hook L, Spivack C, Duncanson FP. Acquired Pelger-Huët anomaly associated with *Mycoplasma pneumoniae* pneumonia. Am J Clin Pathol 1985;84(2):248–251.
- Barton AM, MacLeod BC, Thomas ED. Transfer of Pelger-Huët anomaly by bone marrow transplantation. Am J Hematol 1982;13:163–166.
- Masat T, Feliu E, Tassies D, Rovira M, Granena A, Rozman C. Pseudo-Pelger-Huët anomaly after bone marrow transplantation. Hematol Pathol 1991;5(2):89–91.
- Gondo H, Okamura C, Osaki K, Shimoda K, Asano Y, Okamura T. Acquired Pelger-Huët anomaly in association with concomitant tacrolimus and fluconazole therapy following allogeneic bone marrow transplantation. Bone Marrow Transplant 2000;26(11):1255–1257.
- Harm H. Beeinflussung des weißen Blutbildes von Pelger- und Nicht-Pelger-Kaninchen durch Colchicin. Acta Haematol 1953;10:95–105.
- Shanbrom E, Collins Z, Miller S. ‘Acquired’ Pelger-Huët cells in blood dyscrasias. Am J Med Sci 1960;240:732–738.
- Kaplan JM, Barrett OJ. Reversible pseudo-Pelger anomaly related to sulfisoxazole therapy. New Engl J Med 1967;277(8):421–422.
- Polite ALJ. Drug-induced morphological changes. Am J Med Technol 1975;41(3):130–131.
- Levin JM. Pelger-Huët anomaly and D-penicillamine treatment. J Rheumatol 1980;7(3):418–420.
- Deutsch PH, Mandell GL. Reversible Pelger-Huët anomaly associated with ibuprofen therapy. Arch Intern Med 1985;145:166.
- Rüthlein J, Meesmann M, Gunzer U, Auer IO. Nomifensin-induziertes Fieber mit Perikarderguß, basalem Lungeninfiltrat und Pseudo-Pelger-Huët-Anomalie. Med Klin 1986;81(18–19):619–622.
- Teshima T, Shibuya T, Harada M, et al. Effects of G-CSF, GM-CSF, and Il-5 on nuclear segmentation of neutrophils and eosinophils in congenital or acquired Pelger-Huët anomaly. Exp Hematol 1991;19:322–325.
- May RB, Sunder TR. Hematologic manifestations of long-term valproate therapy. Epilepsia 1993;34(6):1098–1101.
- Juneja SK, Mathews JP, Luzinat R, et al. Association of acquired Pelger-Huët anomaly with taxoid therapy. Br J Haematol 1996;93:139–141.
- Banerjee R, Halil O, Bain B, Cummins D, Banner N. Neutrophil dysplasia caused by mycophenolate mofetil. Transplantation 2000;70:1608–1610.
- Undritz E. Planches d’hématologie Sandoz. 2nd edition. Basel: Frobenius SA; 1972.
- Haverkamp Begemann N, van Lookeren Campagne A. Homozygous form of Pelger-Huët’s nuclear anomaly in man. 1952;7:295–303.
- Stobbe H. Beobachtungen an vitalen Pelger-Zellen. Schweiz Med Wochenschr 1959;89(41):1085–1088.
- Stobbe H, Jorke D. Befunde an homozygoten Pelger Merkmalsträgern. Schweiz Med Wochenschr 1965;95(41):1085–1087.
- Aznar J, Vaya A. Homozygous form of the Pelger-Huët leukocyte anomaly in man. Acta Haematol 1981;66(1):59–62.
- Siegert E, Beier L, Gräbner H. Ein Beitrag zur homozygoten Form der Pelger-Huët’schen-Kernanomalie. Kinderarztl Prax 1983;51(4):164–169.
- Davidson W, Lawler S, Ackerley A. The Pelger-Huët anomaly: investigation of family ‘A’. Ann Hum Genet 1954;19:1–9.
- Edwards J, Aronson J. Adverse drug reactions: definitions, diagnosis, and management. Lancet 2000;356:1255–1259.
- Radomska-Pandya A, Czernik PJ, Little JM, Battaglia E, Mackenzie PI. Structural and functional studies of UDP-glucuronosyl transferases. Drug Metab Rev 1999;31(4):817–899.
- Allison AC, Eugui EM. Immunosuppressive and other effects of mycophenolic acid and an ester prodrug, mycophenolate mofetil. Immunol Rev 1993;136:5–28.
- Al-mohizea AM, Subbotin VM, Murase N, Venkataraman R. Acute rejection of liver impairs the activity of UGT1A9 in rats. Drug Metab Rev 2001;33(S1):160.
- Sanchez J, Wangh L. New insights into the mechanisms of nuclear segmentation in human neutrophils. J Cell Biochem 1999;73:1–10.